

See discussions, stats, and author profiles for this publication at: <https://www.researchgate.net/publication/7692682>

Neurophysiologic features in glutaric aciduria type I

Article in *The Turkish journal of pediatrics* · April 2005

Source: PubMed

CITATIONS

2

READS

152

5 authors, including:



Dilek Yalnizoglu

Hacettepe University

77 PUBLICATIONS 1,278 CITATIONS

[SEE PROFILE](#)



Neriman Sari

Dr. Abdurrahman Yurtaslan Oncology Training and Research Hospital

34 PUBLICATIONS 321 CITATIONS

[SEE PROFILE](#)



Güzide Turanlı

Hacettepe University

65 PUBLICATIONS 824 CITATIONS

[SEE PROFILE](#)



Meral Topçu

Hacettepe University

211 PUBLICATIONS 4,922 CITATIONS

[SEE PROFILE](#)

Some of the authors of this publication are also working on these related projects:



Joubert Syndrome and Related Disorders [View project](#)



Ewing sarcoma [View project](#)

Neurophysiologic features in glutaric aciduria type I

Dilek Yalnızođlu¹, Neriman Sarı¹, Güzide Turanlı¹, Turgay Coşkun², Meral Topçu¹

¹Sections of Pediatric Neurology, and ²Nutrition and Metabolism, Department of Pediatrics, Hacettepe University Faculty of Medicine, Ankara, Turkey

SUMMARY: Yalnızođlu D, Sarı N, Turanlı G, Coşkun T, Topçu M. Neurophysiologic features in glutaric aciduria type I. Turk J Pediatr 2005; 47: 153-158.

Neurophysiologic abnormalities are frequently seen in organic acidemias, but knowledge of the specific changes in the different types of organic acidemias is lacking. We studied electroencephalogram (EEG), visual evoked potential (VEP) and brain-stem auditory evoked response (BAER) in seven children with glutaric aciduria type I (GA1) to assess the neurophysiologic features in this rare inborn error of metabolism.

Age at the time of the diagnosis ranged between 3 months and 36 months. Age at the time of neurophysiologic evaluation ranged between 11 months and 36 months. At the time of neurophysiologic evaluation, severe global developmental delay was seen in four patients, dystonia in four patients, motor delay in two patients, and axial hypotonia in two patients; macrocephaly, spasticity, moderate mental retardation and borderline intelligence were each seen in one patient. One patient had autistic features characterized by lack of language and social skills, poor eye contact and stereotypical behavior.

Three of seven patients showed abnormal EEG findings. Two patients showed asymmetry with intermittent occipital delta slowing in one hemisphere. This finding probably indicates underlying cerebral dysfunction, and is not a specific feature. However, it suggests that these patients may develop abnormal EEG features during the course of the disease, and thus a baseline EEG may be useful for comparison over time. One patient showed high amplitude bursts of beta in the occipital regions with left predominance while on clonazepam and baclofen. We believe this finding was due to medication effect, and that what we observed was an exaggerated response to benzodiazepine. The clinical significance of this finding is unclear. VEP and BAER were available in four patients, and we found abnormalities in three of them. Neurophysiologic evaluation may be helpful in patients with GA1 as in other types of organic acidemias to help detect subtle changes that are not reflected by neurological examination or neuroimaging studies, and it may guide future treatment plans. Detailed neurophysiologic analysis in a large series of GA1 may yield further information regarding the extent of cerebral dysfunction.

Key words: glutaric aciduria type I, metabolic disorders, organic acidemias, electroencephalogram, visual evoked potential, brain stem auditory evoked response, neurophysiology.

Glutaric aciduria type I (GA1) is a disorder of organic acid metabolism caused by glutaryl Co-A dehydrogenase deficiency, a mitochondrial matrix enzyme that degrades two essential amino acids, lysine and tryptophan. Although the majority of oxidation of these two amino acids occurs in the liver and kidney, the brain is the principal organ affected¹. Clinical outcome and natural history of the disorder have been thoroughly studied^{1,2}.

Neurophysiologic abnormalities are frequently seen in organic acidemias, but knowledge of the specific changes in the different types of organic acidemias is lacking. There are a few case reports with limited neurophysiologic information, and a large survey with a wide spectrum of organic acidemias³; however, the numbers of patients with each of the different types of organic acidemias for the most part remain small. We studied electroencephalogram

(EEG), visual evoked potential (VEP) and brain-stem auditory evoked response (BAER) in GA1 to assess the neurophysiologic features in this rare inborn error of metabolism.

Material and Methods

We report neurophysiological findings in seven children with GA1 diagnosed and followed at Hacettepe University Faculty of Medicine Department of Pediatrics, Sections of Neurology, and Nutrition and Metabolism. The diagnosis of GA1 was based on clinical and neuroimaging findings, and was confirmed by urine organic acid analysis by gas chromatography-mass spectrometry.

All patients had routine EEG with 8 or 21 channel machines using 10-20 electrode placements. Follow-up EEG was available in one patient. EEGs were limited to sleep recordings in six patients and waking state in one patient. VEP and BAER were obtained in four patients as described previously⁴. Neuroimaging studies were available in six patients; two patients had magnetic resonance imaging (MRI), two had computerized tomography (CT), and two had both. Clinical and laboratory data at the time of the diagnosis as well as neuroimaging findings were obtained by medical chart review.

Results

Seven patients came from six families; consanguinity between parents was present in four families. Patients 1 and 2 were monozygotic twin sisters. Male to female ratio was 4/3. Age at the time of the diagnosis ranged between 3 and 36 months (mean: 13.95 months, median: 9 months). Age at the time of neurophysiologic evaluation ranged between 11 and 36 months (mean: 22.95 months, median: 21 months). Demographic data, clinical features, neuroimaging studies and neurophysiological findings are summarized in Table I.

Clinical Presentation and Neurological Findings

Three patients who were previously healthy presented with encephalopathic crisis. The two patients who were monozygotic twin sisters presented with vomiting and diarrhea 2-3 days after polio vaccination at 14 months. One of them additionally had right-sided weakness and loss of head control. One patient had encephalopathic crisis at 10 months with fever,

vomiting, and diarrhea, together with seizures, metabolic acidosis and ketosis. He then developed dystonia involving trunk, neck and both upper extremities which was initially misdiagnosed as seizures. Two patients presented with global developmental delay at three months and nine months. One patient (Patient 6) was brought for medical attention relatively late, at three years of age, with lack of language, speech and social skills, although he had a history of early developmental delay. He also had dysmorphic facial features with hypertelorism, prominent ears, and macrocephaly. He had a history of corrective surgery for congenital heart defect at 19 months of age in another center, before he was diagnosed with GA1. He had ventricular septal defect and aortic insufficiency. One patient presented with motor delay at 11 months which was noted as early as 7 months; he additionally had irritability and sleep problems.

At the time of neurophysiologic evaluation, severe global developmental delay was seen in four patients, dystonia in four patients, motor delay in two patients, and axial hypotonia in two patients; macrocephaly, spasticity, moderate mental retardation and borderline intelligence were each seen in one patient. One patient had autistic features characterized by lack of language and social skills, poor eye contact and stereotypical behavior.

Neurophysiologic Findings

Three patients had normal sleep EEGs, and one had normal waking record for age. Two patients showed asymmetry with intermittent high amplitude occipital 2-2.5 Hz delta slowing during sleep in one hemisphere (Fig. 1). One patient (Patient 3) had high amplitude beta bursts, at times sharply contoured, resembling spike bursts, followed by slow waves in the bilateral occipital regions during sleep (Fig. 2). This patient was on clonazepam and baclofen for severe spasticity and dystonia. He had another EEG after six months which showed diffuse excessive beta activity predominantly in the anterior regions, and no other abnormalities. His initial EEG obtained at the time of encephalopathic crisis was not available for our review; it was read as abnormal due to irregular background activity and mild paroxysmal features.

Table I. Summary of Clinical Features, Neuroimaging and Neurophysiologic Findings

Case	Age ^a (months)	Age at diagnosis (months)	Sex	Clinical presentation	Neurological findings	CT	MRI	EEG	VEP	BAER
1 ^b	22	14	F	+ Vomiting, diarrhea, loss of head control and right sided weakness following polio vaccination	Motor delay, dystonia	N	NA	Right occipital high amplitude 2-2.5 Hz delta slowing during stage 2 sleep	N	Wave I shows low amplitude and delayed latency on the right
2 ^b	22	14	F	+ Vomiting, weakness following polio vaccination	Motor delay, dystonia	N	NA	N waking	N	Wave I shows delayed latency in the left, delayed I-V inter peak latency on the right
3	12	10	M	+ Fever, diarrhea, vomiting, lethargy, seizures, metabolic acidosis, ketosis	Global DD, loss of previously gained milestones, dystonia, spasticity	Frontotemporal atrophy	Bilateral frontal subdural collection, enlarged Sylvian fissures bilaterally, leukodystrophy, bilateral dentate nuclei and basal ganglia lesions	Bilateral posterior intermittent bursts of sharply contoured high amplitude beta bursts with left predominance in sleep	N	N
4	21	9	M	+ DD, weakness	Global DD, predominantly in motor skills, hypotonia	NA	NA	Normal sleep	Delayed P1 latency on the right	Delayed I-V interpeak latency on the left
5	36	3	F	- DD	Macrocephaly, borderline IQ	NA	Leukodystrophy, bilateral basal ganglia lesions	Left occipital delta slowing in stage 2 sleep	NA	NA
6	36	36	M	- Lack of speech, language and social skills	Global DD, moderate mental retardation, poor eye contact, stereotypical behavior	NA	Cerebral and cerebellar atrophy	Normal sleep	NA	NA
7	11	11	M	+ Motor delay, sleep problems, irritability	Global DD, hypotonia, dystonia	Bilateral temporal arachnoid cyst	Bilateral dentate nuclei, lentiform nuclei, posterior thalami, pontine tegmentum lesions, leukodystrophy, bilateral temporal arachnoid cysts, enlarged Sylvian fissures	Normal sleep	NA	NA

a: Age at the time of clinical and neurophysiologic evaluation, b: patients 1 and 2 are monozygotic twin sisters, C: consanguinity, EEG: electroencephalography, CT: computerized tomography, DD: developmental delay, MRI: magnetic resonance imaging, VEP: visual evoked potentials, BAER: brain-stem evoked response, F: female, M: male, IQ: intelligence quotient, N: normal, NA: not available.

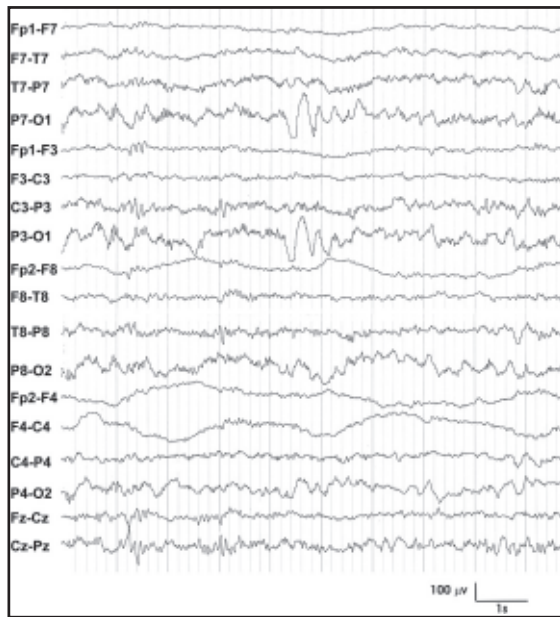


Fig. 1. EEG showing asymmetry with left occipital delta slowing in sleep (Patient 5).

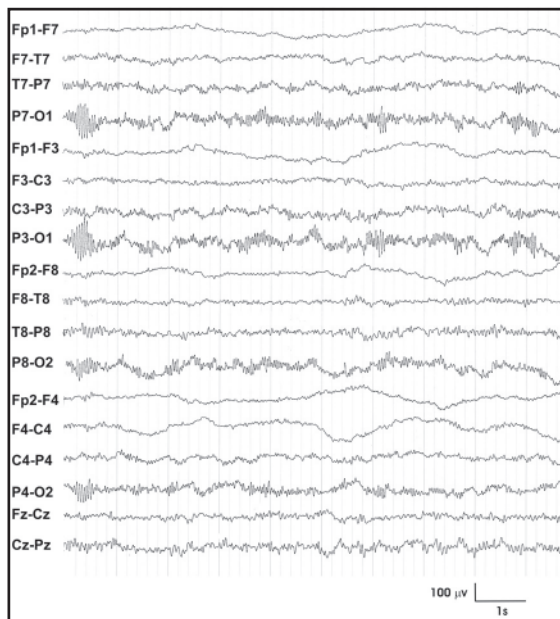


Fig. 2. EEG showing bursts of high amplitude sharply contoured fast activity in the occipital regions more pronounced over the left (Patient 3).

Discussion

Glutaric aciduria type I is a disorder of organic acid metabolism first described in 1975 by Goodman et al.⁵. GA1 shows autosomal recessive inheritance and is caused by mutations

in glutaryl-CoA dehydrogenase gene on chromosome 19p13.2. It is biochemically characterized by elevated urinary excretion of glutaric acid, 3-hydroxyglutaric acid, and glutarylcarnitine; reduced plasma carnitine; and reduced or absent glutaryl-CoA dehydrogenase activity in fibroblasts and leukocytes. GA1 is typically a disease of infancy and childhood with onset during the first three years of life. Our patients presented between three months and three years of age. Encephalopathic crisis was the first sign in three of seven patients. The other four patients suffered from developmental delays in varying degrees; delay in motor skills was more prominent. Dystonia was seen in four patients, in agreement with previous observations. In GA1, motor deficits such as dystonia and dyskinesia are seen along with developmental delays⁶. In some patients, symptoms are triggered by a precipitating illness or vaccination^{7,8}. Cognitive function and social affect are relatively preserved; however, motor disabilities may limit correct evaluation^{7,9}.

Electroencephalographic studies in GA1 show unspecific slowing during an encephalopathic crisis, after which they usually remain within normal limits¹⁰. Four of seven patients in our series had normal EEGs. However, three of the normal recordings were limited to sleep state, therefore we cannot comment on awake background. The remaining fourth patient showed normal awake background for age, but no sleep recording was obtained. Three patients showed abnormal EEG findings. Two patients showed asymmetry with intermittent occipital delta slowing in one hemisphere. One of these patients was the twin sister of the patient with normal awake EEG. This finding probably indicates underlying cerebral dysfunction, and is not a specific feature. However, it suggests that these patients may develop abnormal EEG features during the course of the disease, and thus a baseline EEG may be useful for comparison over time. Stigsby et al.³ reported neurophysiologic correlates of organic acidemias in a survey 107 patients. They had seven patients with GA1, all of whom had normal EEGs initially. Four were followed for up to 2.5 years and one showed slowing of background during a period with many seizures; others continued to have normal EEGs. Compared to the degree of neurological and neuroradiological involvement in our patients, their EEG features could be considered

relatively mild. Curiously, one patient showed high amplitude bursts of beta in the occipital regions with left predominance. Paroxysmal high amplitude beta bursts at times had a very sharp contour which almost resembled spike bursts, and when admixed with the slow waves of normal sleep background, they resembled polyspike and waves. This patient had seizures during encephalopathic crisis, and was treated with antiepileptic drugs for acute management of seizures, but did not require long-term treatment. At the time of EEG study, he was on clonazepam and baclofen for treatment of severe spasticity and dystonia. We believe these EEG findings were due to medication effect, and that what we observed was an exaggerated response to benzodiazepine. The benzodiazepine derivatives are potent activators of beta activity in EEG. Benzodiazepine-induced fast activity is reduced over the region of cerebral lesion¹¹. Baclofen is a selective GABA-B receptor agonist used for treatment of spasticity. Oral therapeutic doses did not increase seizure frequency in chronic epileptic patients¹²; however, seizures were observed with intrathecal baclofen application¹³. To our knowledge, EEG changes with medication effect in different metabolic disorders have not been studied; findings with benzodiazepines in GA1 were not reported previously.

VEPs were recorded in four patients and were normal in three. One patient had delayed P100 latency in the right (Fig. 3). Stigsby et al.³ found normal VEP results in five of six patients with GA1. One patient had prolonged P100 latency, and it was concluded that VEP recorded during sedated sleep might contribute to prolonged latency. Three of four BAER recordings were abnormal, whereas Stigsby et al.³ reported five of seven to be normal. In our series, two patients who were twin sisters had low amplitude prolonged wave I, and one of them additionally had prolonged I-V interpeak latency. One patient merely had prolonged I-V interpeak latency (Fig. 4). The clinical usefulness of evoked potential studies is localization of central nervous system involvement; generally brainstem involvement can be recognized with BAER and centrum semiovale with VEP. These tests were found helpful in classifying patients with organic acidemias³; in pyruvate dehydrogenase deficiency there was involvement of the centrum semiovale and the brain-stem, whereas in pyruvate

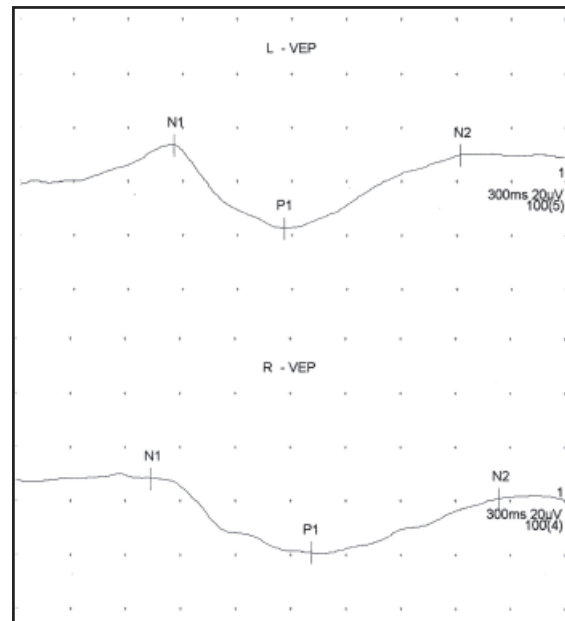


Fig. 3. Visual evoked potential study of Patient 4 showing delayed P100 latency on the right.

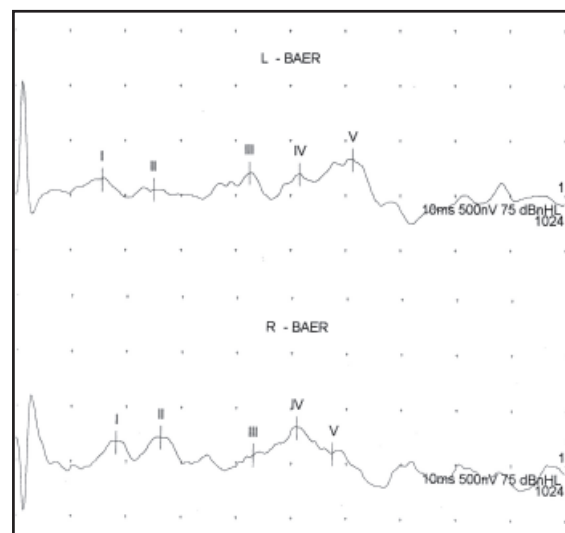


Fig. 4. Brain stem auditory evoked response showing prolonged I-V interpeak latency on the left (Patient 4).

carboxylase deficiency both VEP and BAER were usually normal. Our evoked potential results suggest brainstem involvement in two of four

patients. Unfortunately, no MRI studies were done in these three patients for evaluation of white matter abnormalities.

Overall our observations of normal EEGs in most of our patients are in agreement with previous reports^{3,14-16}. Our patients additionally showed mild EEG abnormalities suggestive of cerebral dysfunction. One patient on clonazepam showed excessive beta in the posterior head regions, thought to be an exaggerated response to benzodiazepine. The clinical significance of this finding is unclear. VEP and BAER were available in four patients and we found abnormalities in all patients but one. Stigsby et al.³ concluded that the magnitude and frequency of neuro-physiological abnormalities in organic acidemias were such that neurophysiological tests would still have a place in the patient investigation and in the monitoring of treatment response; because they provide additional information complementing the structural information from neuroimaging studies. We believe neuro-physiologic evaluation may be helpful in patients with GA1 as in other types of organic acidemias to help detect subtle changes that are not reflected by neurological examination or neuroimaging studies, and it may guide future treatment plans. Detailed neurophysiologic analysis in a large series of GA1 may yield further information regarding the extent of cerebral dysfunction.

Acknowledgements

Dr. Dilek Yalınzoğlu is supported by NIMH ICORTHA Fogarty International Mental Health and Developmental Disabilities (MH/DD) Research Training Program (D43TW05807) at Children's Hospital Boston, PI: Kerim M. Munir.

REFERENCES

1. Straus KA, Puffenberger EG, Robinson DL, Morton DH. Type I glutaric aciduria part 1: natural history of 77 patients. *Am J Med Genet (Sem Med Genet)* 2003a; 121C: 35-52.
2. Bjugstad KB, Goodman SI, Freed CR. Age at symptom onset predicts severity of motor impairment and clinical outcome of glutaric acidemia type 1. *J Pediatr* 2000; 137: 681-686.
3. Stigsby B, Yarworth SM, Rahbeeni Z, et al. Neurophysiological correlates of organic acidemias: a survey of 107 patients. *Brain Dev* 1994; 16 (suppl): 125-144.
4. Coşkun T, Topçu M, Üstün İ, et al. Neurophysiological studies of patients with classical phenylketonuria. Evaluation of results of IQ scores, EEG and evoked potentials. *Turk J Pediatr* 1993; 35: 1-10.
5. Goodman SI, Markey SP, Moe PG, Miles BS, Teng CC. Glutaric aciduria: a 'new' disorder of amino acid metabolism. *Biochem Med* 1975; 12: 12-21.
6. Hoffman GE, Bohles HJ, Burlina A, et al. Early signs and course of disease of glutaryl-CoA dehydrogenase deficiency. *J Inheret Metab Dis* 1995; 18: 173-176.
7. Goodman SI, Biery BJ. Glutaric acidemia (type I). *Ment Retard Dev Disabil Res Rev* 1996; 2: 155-159.
8. Fujimoto S, Shibata H, Sugiyama N, Ohba S, Togari H, Wada Y. Unique electroencephalographic change of acute encephalopathy in glutaric aciduria type I. *Tohoku J Exp Med* 2000; 191: 31-38.
9. Kyllerman M, Skjeldal OH, Lundberg M, et al. Dystonia and dyskinesia in glutaric aciduria type 1: clinical heterogeneity and therapeutic considerations. *Mov Disord* 1994; 9: 22-30.
10. Superti-Furga A, Hoffmann GF. Glutaric aciduria type I (glutaryl-CoA-dehydrogenase deficiency): advances and unanswered questions. *Eur J Pediatr* 1997; 156: 821-828.
11. Gotman J, Gloor P, Quesney LF, Olivier A. Correlations between EEG changes induced by diazepam and the location of epileptic spikes and seizures. *Electroencephal Clin Neurophysiol* 1982; 54: 614-621.
12. Terrence CF, Fromm GH, Roussan MS. Baclofen. Its effect on seizure frequency. *Arch Neurol* 1983; 40: 28-29.
13. Kofler M, Kronenberg MF, Rifici C, Saltuari L, Bauer G. Epileptic seizures associated with intrathecal baclofen application. *Neurology* 1994; 44: 25-27.
14. Gregersen N, Brandt NJ, Christensen E, Gron I, Rasmussen K, Brandt S. Glutaric aciduria: clinical and laboratory findings in two brothers. *J Pediatr* 1977; 90: 740-745.
15. Seccombe DW, James L, Booth F. L-Carnitine treatment in glutaric aciduria type I. *Neurology* 1986; 36: 264-267.
16. Amit R, Berginer J, Shapira Y. CT in glutaric aciduria. *Neurology* 1990; 40: 188-189.